

## Trisomy 16q23→qter arising from a maternal t(13;16)(p12;q23): case report and evidence of the reciprocal balanced maternal rearrangement by the Ag-NOR technique

J. B. Savary<sup>1</sup>, F. Vasseur<sup>1</sup>, S. Manouvrier<sup>2</sup>, A. Daudignon<sup>1</sup>, O. Lemaire<sup>1</sup>, M. Thieuleux<sup>3</sup>, M. Poher<sup>3</sup>, P. Lequien<sup>4</sup>, and M. M. Deminatti<sup>1</sup>

<sup>1</sup>Service de Génétique Humaine et Pathologie Fœtale, Faculté de Médecine, 1, Place de Verdun, F-59045 Lille Cedex, France

<sup>2</sup>Service de Pédiatrie, Hôpital Huriez, CHU, 1, Place de Verdun, F-59045 Lille Cedex, France

<sup>3</sup>Service de Néonatalogie, Centre Hospitalier de Calais, 11, Quai du Commerce, B.P. 339, F-62207 Calais Cedex, France

<sup>4</sup>Centre de Prématurés, Hôpital Calmette, Boulevard du Professeur J. Leclercq, F-59037 Lille Cedex, France

Received March 3, 1991 / Revised June 11, 1991

**Summary.** We describe a female new-born with partial trisomy of the long arm of chromosome 16. The chromosome anomaly was the result of an unbalanced segregation of a maternal translocation t(13;16)(p12;q23). Dynamic (RBG, GBG) banding and the Ag-NOR technique ascertained the reciprocal balanced maternal translocation between the 16q23→qter and 13q12→pter segments because nucleolar organizers were present on the tip of long arms of the derivative 16 maternal chromosome. As monosomy 13p has little or no deleterious effect we consider our case as exhibiting the phenotype of trisomy 16q23→qter free from any monosomic feature. Clinical effects are of less consequence as compared with previously published cases of partial trisomy 16q.

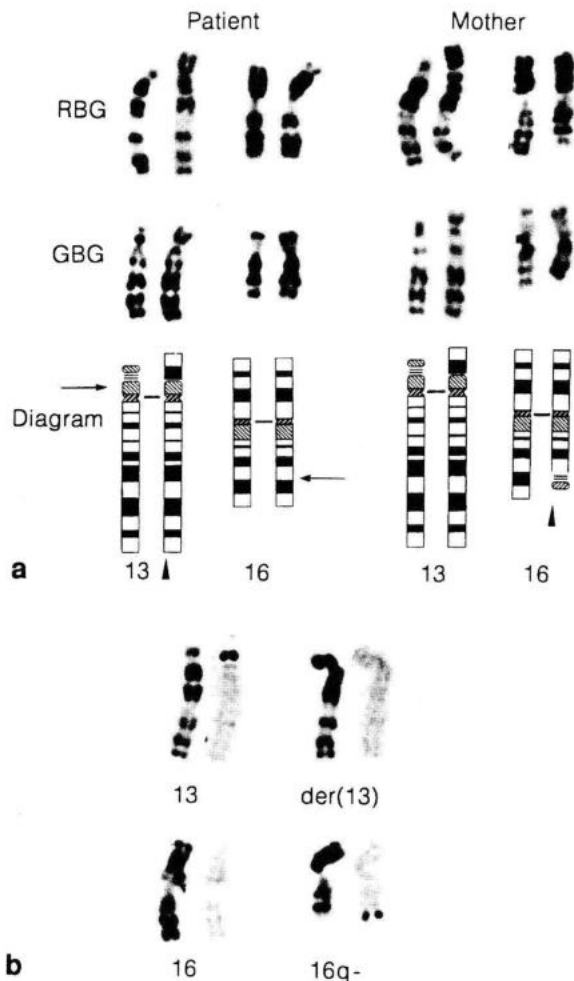
### Introduction

Complete trisomy 16 is commonly recognized among spontaneous abortions (Boue and Boue 1975; Creasy et al. 1976) accounting for 28% in abortion surveys (Kajii et al. 1980) and suggesting that autosomal trisomy 16 is not compatible with live birth. Although complete trisomy 16q is rare in live born infants (Schmickel et al. 1975), 17 cases with partial trisomy 16q have been described. They were compatible with term survival below a month (Eriksson et al. 1971; Ridler and Mc Keown 1979; Garau et al. 1980; Buckton and Barr 1981; Davison and Beesley 1984), with term survival up to 1 year (Francke 1972; Hirai et al. 1981; Rethore et al. 1982; Davison and Beesley 1984; Nevin et al. 1983; Hatanaka et al. 1984), and with term survival beyond 1 year (Balestrazzi et al. 1979; Rethore et al. 1982; Calva et al. 1984; Les-

sick et al. 1989; Dowman et al. 1989). Except for the case of Hirai et al. (1981) patients with partial 16q trisomy resulted from unbalanced segregation of a parental translocation. In this paper we report a trisomy 16q23→qter in a liveborn girl as a result of a maternal translocation t(13;16)(p12;q23). The clinical features of this trisomy were assumed to be free from any associated monosomic effect and were compared with previously described cases of partial trisomy 16q.

### Case report

Jodie D. was born on 13th July, 1990 at 34 weeks of gestation. Familial history was without any particularity. The baby was the first born infant of 26 year-old healthy unrelated parents. To our knowledge there was no hypofertility as in previously reported cases. Neither spontaneous abortions nor abnormal fetuses had been noticed in this couple. At birth the proposita weighted 2500 g, with a body length of 45.5 cm and a 32 cm head circumference. The shape of skull was distorted because of a cephalhematoma related with forceps delivery. Apgar scores were 1 both at 1 and 5 min. Fetal distress required external cardiac massage, artificial ventilation for a 90 min period and then oxygen administration during 60 h. There were no visceral malformations. Bacteriological investigations revealed a meningitis. Antibiotic treatment resulted in rapid clinical progress. Because of hypotonia and dysmorphic features a karyotype was made at age 6 days. At age 4 months the girl weighed 5000 g (-1.5 SD); had a length of 59 cm (-1 SD) with a 39.5 cm head circumference (-0.5 SD). The child was hypotonic, could not hold things, but smiled to her parents and began to babble so that at this time it was difficult to conclude that developmental milestones were retarded. Physical examination revealed a dysmorphic syndrome including a high forehead with a large frontal angioma, a small and narrow nose with a depressed nasal bridge, anteverted nostrils and thick columella, hypertelorism, lightly up-slanting short palpebral fissures, normal-set ears with bad-lobulated helices and a prominent anthelix, normal palate but thickened gingivæ, finger pads and proximal implantation of first toes.



**Fig. 1a, b.** Chromosomes 13 and 16 of the proband and her mother with RBG and GBG banding and a schematic G-banding representation showing the partial trisomy, 16q23→qter, in the affected patient and the translocation in her mother. ▲ derivative chromosomes. The breakpoints in 13p12 and 16q23 are indicated by an arrow (a). Partial karyotype of the mother showing RBG chromosomes on the left, and the same chromosomes with the Ag-NOR technique on the right (b)

## Cytogenetic investigations

Peripheral blood cultures were set up from the baby and both parents. Chromosome identification was achieved with dynamic banding (RBG, GBG) using 5 Bromodeoxyuridine (5 BrdU) pulse-incorporation according to Dutrillaux and Couturier (1981). Nucleolar organizer regions (NORs) were stained as described by Howell and Black (1980). The proband had a 46,XX,-13,+der(13) karyotype. One chromosome 13 showed extra material on the short arm (Fig. 1a). The father had a normal 46,XY constitution. Chromosome examination of the mother revealed a balanced 13;16 translocation  $t(13;16)(p12;q23)$  with extra material on the short arm of one chromosome 13 and with one chromosome 16 deleted for the  $q23\rightarrow qter$  segment (Fig. 1a). With the Ag-NOR technique every acrocentric chromosomes of the mother had Nors+ except the abnormal chromosome 13. Nucleolar organizers were present at the tip of the long arm of the 16q- maternal chromosome (Fig. 1b) and identified the maternal reciprocal translocation as  $t(13;16)$ . Both chromosomes 16 of the proband were normal and no nucleolar organizer was present on her abnormal chromosome 13. Thus she was trisomic for the region 16q23→qter as shown in the G-banded diagram (Fig. 1a). This abnormal constitution was the result of unbalanced segregation of a maternal translocation:  $t(13;16)(p12;q23)$  mat.

## Discussion

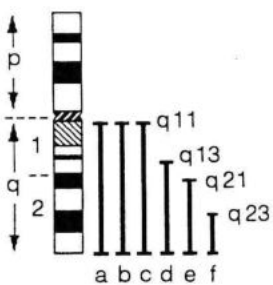
To our knowledge 17 cases with partial 16q trisomy have been previously reported but the phenotype was difficult to delineate because 12 of them were associated with monosomy or trisomy for another chromosomal segment (Table 1). The five remaining cases and our case may be considered free from any associated monosomic or trisomic clinical effect because they arose from D/16 or G/16 translocations (four cases) and from a 16q13→q24 direct duplication in one case (Table 2). These cases exhibited various partial trisomy 16q as shown in Fig. 2, the present trisomy 16q23→qter being the smallest in size. Clinical features of these infants showed similarities with the previously partial trisomy 16q syndrome described by Rethore et al. (1982): low birth-weight, hypotonia, failure to thrive, abnormal shape of skull, high prominent forehead, small antimongoloid slanting palpebral fissures, periorbital edema, limb abnormalities, congeni-

**Table 1.** Cytogenetic data of published cases with partial trisomy 16q associated with monosomy or trisomy for a second chromosomal segment

Parental rearrangement	16q trisomic portion	Associated monosomy	Associated trisomy	Authors
$t(16q;18q)$ pat	16q	18q	-	Eriksson et al. (1971)
$t(16;22)(q2;q1)$ pat	16q2→qter	22q1→qter	-	Francke (1972)
$t(16;18)(q21;p11.2)$ pat	16q21→qter	18p11→pter	-	Garau et al. (1980)
$t(9;16)(p24;q13)$ pat	16q13→qter	9p24→pter	-	Buckton and Barr (1981)
$t(16;21)(q22.2;q22.2)$ pat	16q22.3→qter	21q22.3→qter	-	Rethore et al. (1982)
$t(16;21)(q22.2;q22.2)$ pat	16q22.3→qter	-	21pter→q22.1	Rethore et al. (1982)
$t(16;20)(q13;p13)$ pat	16q13→qter	20p13→pter	-	Davison and Beesley (1984)
$t(16;20)(q13;p13)$ pat	16q13→qter	20p13→pter	-	Davison and Beesley (1984)
$t(11;16)(q25;q13)$ pat	16q23→qter	11q25→qter	-	Hatanaka et al. (1984)
$t(11;16)(p15;q22)$ mat	16q21→qter	11p15→pter	-	Calva et al. (1984)
$t(9;16)(p24;q21)$ mat	16q21→qter	9p24→pter	-	Lessick et al. (1989)
$t(9;16)(p24;q13)$ mat	16q13→qter	9p24→pter	-	Dowman et al. (1989)

**Table 2.** Anamnestic data and clinical features of our case and previously described patients with partial trisomy 16q free from monosomy or trisomy for a second chromosomal segment. ASD is atrial septal defect, VSD is ventricular septal defect

	Ridler and McKeown (1979)	Balestrazzi et al. (1979)	Hirai et al. (1981)	Nevin et al. (1983)	Nevin et al. (1983)	Our study
Sex	F	M	F	M	M	F
Gestational age	?	40 weeks	41 weeks	36 weeks	Term	34 weeks
Birth weight	1600 g	2600 g	2160 g	1540 g	2265 g	2500 g
Birth length	43.5 cm	?	47 cm	48 cm	49 cm	45.5 cm
Birth head circumference	29 cm	?	?	32 cm	32.5 cm	32 cm
Parental re-arrangement	t(15;16)(p11;q11)	t(16;22)(q21;p12)	Not exam.	t(15;16)(p12;q11)	t(15;16)(p12;q11)	t(13;16)(p12;q23)
Carrier	Mat	Mat		Mat	Mat	Mat
16q trisomic portion	16q11→qter	16q21→qter	16q13→q24	16q11→qter	16q11→qter	16q23→qter
Survival	12 days	3,5 years	11 months	5 weeks	6 weeks	Living
Abnormal shape of skull	High forehead	High forehead	High forehead	High forehead	High forehead	High forehead
Depressed nasal bridge	Beak like nose	+	+	Nasal bridge full	Nasal bridge full	+
Small palpebral fissures		+		+	+	+
Fissures slant	Antimongoloid	Antimongoloid		Antimongoloid	Antimongoloid	Upward
Hypertelorism		+				+
Micrognathia	+	+	+	+	+	-
Periorbital edema	+	+		+	+	-
Dysplastic ears set	Low	Low	Low		Low	Normal (bad lobulated helices) (prominent anthelix)
Fingers and limbs	Flexion	Flexion	Flexion	Hyperextended fingers, flexed wrists	Hyperextended fingers, flexed wrists	Finger pads
Congenital disease	ASD	-	VSD	Ductus arteriosus		-
Hypotonia		Hypertonia	+	+	+	+
Failure to thrive	+	-	+			
Psychomotor retardation	+	+		+	+	?

**Fig. 2.** Diagrammatic G-banding of chromosome 16 from case reports of partial trisomy 16q free from monosomy or trisomy for a second chromosomal segment. *Straight lines* parallel to the chromosome represent the bands involved in cases reported by Ridler and McKeown 1979 (a); Nevin et al. 1983 (b and c); Hirai et al. 1981 (d); Balestrazzi et al. 1979 (e) and our study (f)

tal heart defect and reduced survival. Our patient was different from the five other cases of partial trisomy 16q free from any associated chromosomal unbalance. Indeed there was no periorbital edema though she had a

large forehead with frontal angioma. Dysplastic ears were normal set with prominent anthelix and palpebral fissures were up-slanting. The absence of congenital heart and visceral defects probably explains the good vital prognosis. It is likely that the less severe clinical effects in our case were related to the small size of the trisomic segment as compared with previously published cases (Fig. 2).

Reciprocal translocations involving the short arm of one acrocentric chromosome requires the establishment of a linear quadrivalent during meiosis (Chandley et al. 1972). This particular configuration promotes segregation disturbances leading to unbalanced embryos which are more or less viable according to the gravity of the chromosomal disorder. Among unbalanced segregations leading to live newborn our observation was the result of an adjacent-1 segregation as previously defined by Hamerton (1971). This segregation pattern is the only one with a good survival prognosis as compared with other unbalanced segregations whose fetal chromosomal consequences are not compatible with life but would pro-

duce spontaneous abortions (i.e., trisomy 13p12→pter with monosomy 16q23→qter, trisomy 13 with monosomy 16pter→q23, trisomy 16pter→q23 with monosomy 13p12→qter). This adjacent-1 segregation producing newborn infants with abnormal phenotype necessitates prenatal diagnosis in this family.

To our knowledge this method was previously used in a case of a 18/21 translocation (Neu et al. 1976) and in a case of a 15/16 translocation (Nevin et al. 1983). In both cases silver staining revealed a NOR included in the acrocentric translocation chromosome. Our cytogenetic case report proves that a NOR may be involved in a reciprocal translocation and become shifted onto another chromosome.

## References

- Balestrazzi P, Giovannelli G, Landucci Rubini L, Dala Piccola B (1979) Partial trisomy 16q resulting from maternal translocation. *Hum Genet* 49:229-235
- Boue A, Boue J (1975) Chromosome abnormalities and abortion. In: Coutinho EM, Fuchs F (eds) *Physiology and genetics of reproduction, part B*. Plenum Press, New York, pp 317-339
- Buckton KE, Barr DGD (1981) Partial trisomy for long arm of chromosome 16. *J Med Genet* 18:483
- Calva P, Frias S, Carnevale A, Reyes P (1984) Partial trisomy 16q resulting from maternal translocation 11p/16q. *Ann Génét (Paris)* 27:122-125
- Chandley AC, Christie S, Fletcher J, Frackiewicz A, Jacobs PA (1972) Translocation heterozygosity and associated subfertility in man. *Cytogenetics* 11:516-533
- Creasy MR, Crolla JA, Alberman ED (1976) A cytogenetic study of human spontaneous abortions using banding techniques. *Hum Genet* 31:177-196
- Davison EV, Beesley JR (1984) Partial trisomy 16 as a result of familial 16;20 translocation. *J Med Genet* 21:384-386
- Dowman C, Lockwood D, Allanson J (1989) Familial translocation t(9;16). *J Med Genet* 26:525-528
- Dutrillaux B, Couturier J (1981) Obtention et marquage des cellules en prophase ou prométhaphase. In: *La pratique de l'analyse chromosomique*. Masson, Paris, pp 62-68
- Eriksson B, Fraccaro M, Hulten M, Lindsten J, Thoren C, Tiepolo L (1971) Structural abnormalities of chromosome 18. II-Two familial translocations, B/18 and 16/18, ascertained through unbalanced forms. *Ann Génét (Paris)* 14:281-290
- Francke U (1972) Quinacrine mustard fluorescence of human chromosomes: characterization of unusual translocations. *Am J Hum Genet* 24:189-213
- Garau A, Crisponi G, Peretti D, Vanni P, Zuffardi O (1980) Trisomy 16q21→qter. *Hum Genet* 53:165-167
- Hamerton JL (1971) *Human cytogenetics. Vol 1: General cytogenetics*. Academic Press, New York London, pp 247-254
- Hatanaka K, Ozaki M, Suzuki M, Murata R, Fujita H (1984) Trisomy 16q13→qter in an infant from a t(11;16)(q25;q13) translocation-carrier father. *Hum Genet* 65:311-315
- Hirai S, Ujiie J, Suzuki J, Hishiyama S, Tsukanishi A, Muramoto J, Kano H, Suzuki H (1981) Duplication of the long arm of chromosome 16. *Jpn J Pediatr* 34:1963-1967
- Howell WM, Black DA (1980) Controlled silver-staining of nucleolus regions with a protective colloidal developer: on one step method. *Experientia* 36:1014-1015
- Kajii T, Ferrier A, Nickawa N, Takahara H, Ohama K, Avirachan S (1980) Anatomic and chromosomal anomalies in 639 spontaneous abortuses. *Hum Genet* 55:87-98
- Lessick ML, Israel J, Wong PWK, Szego K (1989) Partial trisomy 16q secondary to a maternal 9;16 translocation. *J Med Genet* 26:63-64
- Neu RL, Ortega CC, Barg GA, Pinto W Jr, Gardner LI, Howell WM, Denton TE (1976) Inclusion of satellites in an 18/21 translocation chromosome revealed by ammoniacal-silver staining (sat-banding) in a case of partial trisomy 18. *J Med Genet* 13:520-522
- Nevin NC, Coffey WW, Nevin J Mc C, Reid M (1983) Partial trisomy 16q in two boys resulting from a maternal translocation t(15;16)(p12;q11). *Clin Genet* 24:373-379
- Rethore MO, Lafourcade J, Couturier J, Harpey JP, Hamet M, Engler R, Alcindor LG, Lejeune J (1982) Augmentation d'activité de l'adénine phosphoribosyl-transférase chez un enfant trisomique 16q22.2→16qter par translocation t(16;21)(q22.2;q22.2) pat. *Ann Génét (Paris)* 25:36-42
- Ridler MAC, Mc Keown JA (1979) Trisomy 16q arising from a maternal 15p;16q translocation. *J Med Genet* 16:317-319
- Schmickel R, Poznanski A, Himebaugh J (1975) 16q trisomy in a family with a balanced 15/16 translocation. *Birth Defects* 11:229-236